

Treatment of Cervical Spondylotic Radiculopathy with Posterior Percutaneous Endoscopic Cervical Discectomy

Wanqian Zhang¹, Xiangfu Wang^{2*}, Huihui Zheng¹, Weiguo Chen², Heng Zhao¹, Xiangyu You¹, Huanying Yang¹, Gang Zheng¹, Tingrui Sang¹, Chao Zhang¹

¹ Gansu University of Chinese Medicine, Lanzhou, Gansu 730000, China

² Gansu Provincial Hospital of Traditional Chinese Medicine, Lanzhou, Gansu 730050, China

*corresponding author email: wangxf_1969@163.com

Abstract: Purpose Objective to investigate the safety and clinical efficacy of posterior percutaneous endoscopic discectomy (PPECD) in the treatment of cervical spondylotic radiculopathy (CSR). Method from January 2016 to December 2019, 35 cases of CSR were treated with PPECD. The degree of pain was evaluated by numeric rating scales (NRS) before operation, at discharge, 1 month, 3 months, 6 months, 1 year after operation and at the last follow-up. The functional recovery was evaluated by neck disability index (NDI) and Japanese orthopaedic association (JOA). The clinical efficacy was evaluated by modified MacNab grading and MRI at the last follow-up. Result of the 35 patients, 16 males and 19 females were aged 39~78 years, with an average age of (54.0 ± 9.9) years. The operative segments were C4-5 9, C5-6 15 and C6-7 11. All 35 patients successfully completed the operation. The operation time was 60~90min, the average time was (75.0 ± 7.9) min, the bleeding volume was 10~22ml, the average (16.3 ± 3.1) ml, the postoperative hospitalization days were 4~12 days, and the average was (7.0 ± 1.6) days. All 35 patients were followed up for more than one year after operation, with an average follow-up of 26.7 months (13~53 months). The NRS index was significantly lower in each period than before operation ($P < 0.01$), NDI and JOA index were significantly lower than those before operation ($P < 0.01$). The clinical effect was evaluated at the last follow-up, 20 cases were excellent, 12 were good, 3 were fine, and the excellent rate was 91.4%. No complications such as nerve root injury, dural sac tear or infection occurred during the follow-up period, and no patients needed to receive secondary minimally invasive or open surgery for symptom recurrence. Conclusion Under the premise of strictly grasping the indications, the curative effect of PPECD in the treatment of CSR is confirmed, and the patients' satisfaction is high.

Keywords: Cervical spondylotic radiculopathy, percutaneous posterior cervical endoscopy, discectomy, clinical efficacy

Cervical spondylotic radiculopathy is a common cervical spondylosis, accounting for 60% to 70% of all types of cervical spondylosis [1]. Its typical clinical manifestations are upper arm radiation pain and numbness. Most patients can get remission by conservative treatment, but there are still a few patients who need surgical intervention. Anterior cervical discectomy and fusion (ACDF) is the gold standard for the treatment of CRS [2]. However, the loss of intervertebral height, decreased range of motion and adjacent segment degeneration after cervical spine surgery are still problems worthy of attention [3-5]. In recent years, with the continuous popularization of minimally invasive concept in surgery, spinal surgery gradually tends to be accurate and minimally invasive [6]. PPECD has the advantages of small trauma, fast recovery and similar decompression effect of open surgery. Therefore, good clinical curative effect after operation is rapidly promoted [7]. From January 2016 to December 2019, 35 patients with CRS were treated with PPECD in our department. The results of more than one year follow-up were retrospectively studied, and the feasibility and effectiveness were analyzed.

1. Materials and Methods

1.1. Research Objects and General Information

From January 2016 to December 2019, 35 cases of CRS were treated with PPECD under local anesthesia. All patients had unilateral upper limb and finger pain and numbness, with or without neck

and shoulder pain, and decreased muscle strength. There were C4~5 9cases, C5~6 15 cases and C6~7 11 cases. Brachial plexus traction test and / or Spurling sign were positive. There was no history of neck trauma and operation, and no neurological disease. Inclusive criteria [8,9]: (1) typical unilateral single segment nerve root symptoms, imaging showed single segment disc herniation and / or intervertebral foramen stenosis; (2) the symptoms and signs of CSR were consistent with imaging results; (3) conservative treatment for more than 3 months had poor curative effect. Exclusion criteria: (1) cervical spondylotic myelopathy; (2) The neck is obviously accompanied by axial pain ;(3) History of open posterior cervical surgery; (4) Extensive cervical spinal stenosis, ossification of posterior longitudinal ligament or severe calcification of intervertebral disc; (5) The cervical spine dynamic position X-ray showed cervical instability.

Finally, the clinical data of 35 patients with PPECD were collected retrospectively. All patients signed a written informed consent, and the study was approved by the ethics committee of Gansu Provincial Hospital of traditional Chinese medicine.

1.2. Operation Method

All operations were performed by the same surgeon. The patient was prone position, slightly head high sole position, which was conducive to epidural venous reflux and reduced the bleeding in the operation field. Adjust the headstock to fix the head. Under the C-arm fluoroscopy positioning responsibility clearance, body surface marking responsibility clearance and "V" point. Routine disinfection and sheet laying were performed in the operation area. Local infiltration anesthesia was performed at the marked points, and puncture was performed at the side mass of the responsible space. 1 mm Kirschner wire was punctured to the "V" point, and fluoroscopy was used to confirm the responsible clearance. The skin was cut about 7 mm at the puncture point, and the soft tissue expansion cannula and working channel were inserted along the Kirschner wire. Fluoroscopy again to confirm the channel position. The soft tissue was cleaned under endoscope to expose the "V point" (the junction of the responsible lamina space), the upper and lower edges of the lamina were removed by grinding drill under microscope, the lamina window at the "V" point was expanded, the dural sac was fully exposed, and the nerve roots were explored. The free nucleus pulposus could be seen through the axillary part and shoulder of the nerve roots. The nucleus pulposus forceps were removed, and the operation was ended after repeated exploration without residual nucleus pulposus. If combined with nerve root canal stenosis, we can continue to grind out the lateral mass and decompress the nerve root canal. Intradermal suture, sterile dressing paste.

1.3. Postoperative Management and Efficacy Evaluation

All patients were treated with anti-infective and neurotrophic drugs after operation. They were bedridden for 12 to 24 hours. The operation time and intraoperative blood loss were recorded. One day after the operation, the patient got out of bed with the neck support, and the cervical flexion and extension movement was carried out under the guidance of the doctor in our department. One week after the operation, the patient was discharged from hospital and the neck bracket was immobilized for 3~4 weeks. During the follow-up, NRS index was used to evaluate the degree of pain improvement, NDI and JOA index were used to evaluate the functional recovery. Cervical MRI was used to observe nerve root decompression. The clinical efficacy was evaluated by modified MacNab grading at the last follow-up.

2. Statistical Analysis

SPSS25.0 statistical software package was used for statistical analysis. Measurement data: for those who obey normal distribution, paired t test was used to describe the intra group comparison with mean \pm standard deviation ($\bar{x} \pm s$); for those who do not obey, nonparametric rank sum test was used to describe the intra group comparison with "quartile (M(QL,QU))". Count data: using χ^2 test; rank data: using rank sum test, $P < 0.05$, the difference was statistically significant.

3. Result

All the 35 patients completed the operation successfully. No spinal cord, nerve or blood vessel injury, dural tear or other complications occurred. The operation time was 60~90 min. The average

operation time was (75.0 ± 7.9) min. The intraoperative blood loss was 10~22ml, the average blood loss was (16.3 ± 3.1) ml. Postoperative hospital stay was 4-12 days, and the average postoperative hospital stay was (7.0 ± 1.6) d.

3.1. Changes of Physiological Structure

The changes of physiological structure of cervical vertebra before and after operation (see Table 1), the measured values of cervical curvature after operation were significantly larger than those before operation ($P < 0.01$), and the intervertebral height of diseased segments before and after operation had significant changes ($P < 0.01$).

3.2. Pain and Function Evaluation

The NRS, NDI and JOA scores before and after operation are shown in Table 2, Table 3 and Table 4. The results showed that the postoperative NRS and NDI index were significantly decreased ($P < 0.05$), and the JOA index was significantly increased ($P < 0.05$). At discharge, MRI showed that the segmental decompression was good, the nerve root symptoms were significantly relieved in 28 cases and relieved in 7 cases. 35 patients were followed up for an average of 26.7 months (13~53 months). At the last follow-up, the excellent and good rate of 35 patients was 91.4%. MRI showed no recurrence. Typical cases are shown in Figure 1.

Table 1 Comparison of cervical curvature and intervertebral height of diseased segment before and after operation

Time	Cervical curvature (M (Q _L ,Q _U))	The height of intervertebral space of diseased segment (M(Q _L ,Q _U))
Before operation	8.5(8.5,9.2)	5.2(4.9,5.5)
After operation	10.4(9.5,10.5)	4.8(4.6,5.2)
Z	-7.316	-4.344
P	0.000	0.000

Nonparametric rank sum test was used to compare the changes of cervical curvature and intervertebral height before and after operation.

Table 2 NRS score of patients before and after operation

Time quantum	n	NRS($\bar{x} \pm S$)	t	P
Before operation	35	7.9 \pm 0.7		
At discharge	35	2.2 \pm 0.6	22.615	0.000
One month after operation	35	1.8 \pm 0.7	16.233	0.000
3 months after operation	35	1.5 \pm 0.9	10.101	0.000
6 months after operation	35	1.2 \pm 0.8	8.431	0.000
One year after operation	35	0.8 \pm 0.9	5.720	0.000
Last follow-up	35	0.7 \pm 0.9	4.293	0.000

The postoperative NRS scores of each group were compared with preoperative NRS scores by paired t test.

Table 3 NDI scores of patients before and after operation

Time quantum	n	NDI($\bar{x} \pm S$ / M(Q _L ,Q _U))	Z/t	P
Before operation	35	42.2 \pm 2.0		
At discharge	35	23.2 \pm 4.6	30.111	0.000
One month after operation	35	20.4 \pm 4.5	26.934	0.000
3 months after operation	35	17.5 \pm 5.0	20.536	0.000
6 months after operation	35	14.9 \pm 4.7	18.686	0.000
One year after operation	35	11.89(10,12)	0.291	0.000
Last follow-up	35	9.57(8,10)	0.376	0.000

Paired t test and nonparametric rank sum test were used to compare the postoperative and preoperative NDI scores.

Table 4 JOA scores of patients before and after operation

Time quantum	n	JOA($\bar{x} \pm s / M(Q_L, Q_U)$)	Z/t	P
Before operation	35	7.1 \pm 1.0		
At discharge	35	12.1 \pm 0.9	77.764	0.000
One month after operation	35	12.6 \pm 1.0	78.833	0.000
3 months after operation	35	13.6 \pm 1.0	77.761	0.000
6 months after operation	35	14.1 \pm 1.2	71.587	0.000
One year after operation	35	14.66(14,15.)	0.346	0.000
Last follow-up	35	14.94(15,16)	0.372	0.000

Paired t-test and nonparametric rank sum test were used to compare postoperative JOA scores with preoperative JOA scores.

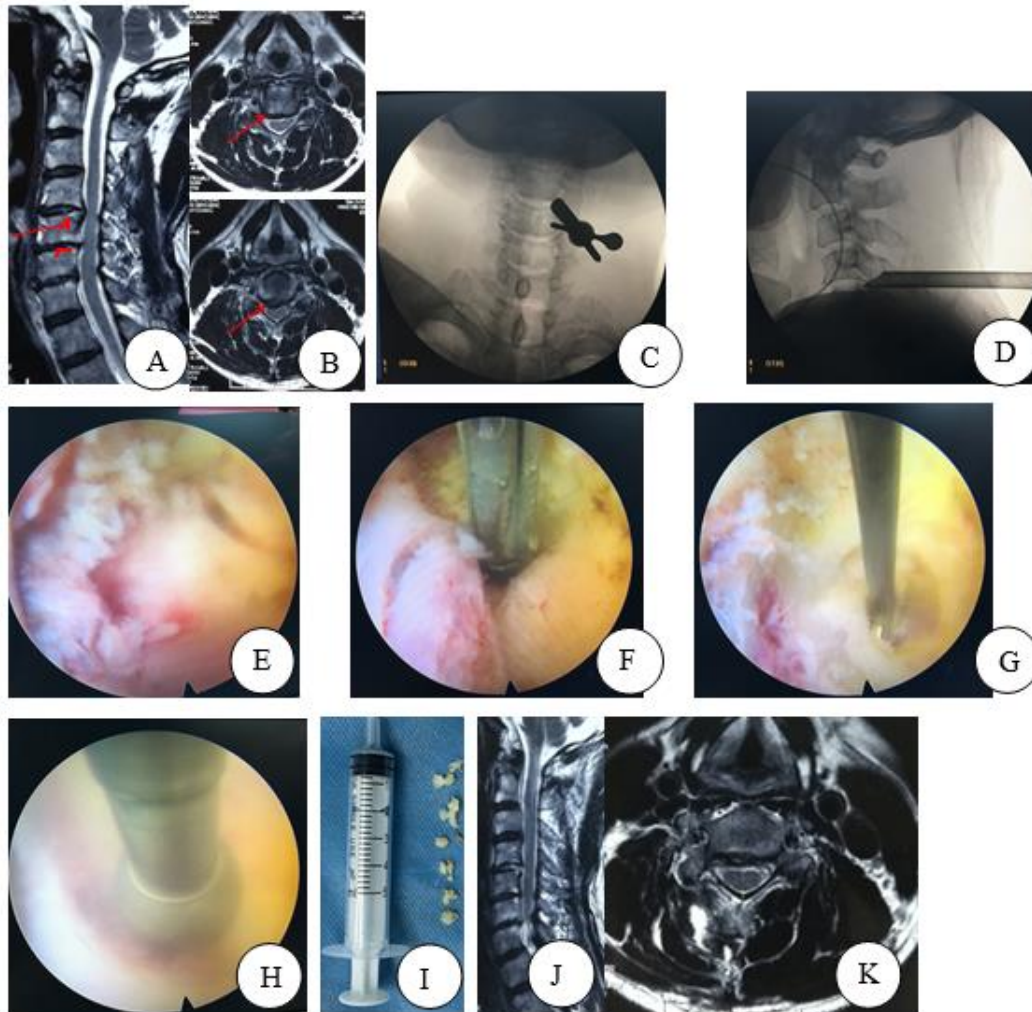


Figure 1: Imaging findings of typical cases of cervical spondylotic radiculopathy before and after operation

A 59 years old female presented with cervical spondylotic radiculopathy (C4-5). A, B: preoperative MRI showed that C4-5 disc herniation was on the right side; C, D,: intraoperative positioning and establishment of working channel; E, F, G, H, I: intraoperative removal of herniated nucleus pulposus tissue; J, K: postoperative MRI showed that C4-5 nucleus pulposus had been removed, local pressure relief.

4. Discussion

The traditional surgical methods for CSR include classic ACDF and posterior open surgery.

Through intraoperative resection of herniated nucleus pulposus or proliferative osteophytes, effective decompression of spinal canal, internal fixation of vertebral body and maintenance of intervertebral height as far as possible [10]. Although studies have reported that open surgery has good clinical efficacy [11,12], there are adjacent segment degeneration and limited motor function after ACDF; after posterior open surgery, due to more muscle dissection, vascular supply and nerve function are damaged, thus increasing the risk of postoperative cervical axial pain and segment instability [13]. In recent years, with the development of minimally invasive spinal surgery and endoscopic instruments, the above problems have been gradually solved. Posterior cervical spinal endoscopic surgery has developed into a safe and effective minimally invasive spinal surgery, which has been gradually widely used in clinical practice.

Lee et al. [14] reported 37 patients with single level CSR who received PPECD treatment. Although postoperative imaging showed cervical intervertebral height, corresponding vertebral degeneration, and decreased cervical mobility, the clinical efficacy of the patients at the last follow-up was significantly improved. Long term follow-up found that the loss of intervertebral disc height and intervertebral disc degeneration did not affect the prognosis of the patients. The most significant advantages of percutaneous endoscopic cervical discectomy are less tissue trauma and faster recovery. The surgical approach can be divided into anterior approach and posterior approach. The factors that affect the surgical approach include [15]: (1) the location of cervical disc herniation. For central or paracentral disc herniation, anterior approach is preferred. For intervertebral foramen or extreme lateral disc herniation, the posterior approach is the first choice; (2) whether combined with cervical foramen stenosis, the effect of anterior approach is not good; (3) anesthesia, the anterior approach can be carried out under local or general anesthesia, and the posterior approach is generally limited to general anesthesia.

Yang et al. [16] treated 42 patients with single segment CRS by percutaneous endoscopic discectomy through different anterior and posterior approaches. The clinical results of the two groups were significantly improved after surgery, and the difference between the two approaches was not significant. However, considering the factors of less vascular injury, sufficient spinal decompression, rapid postoperative recovery, less complications, short hospital stay and low cost, posterior endoscopic cervical discectomy may be more desirable and can be used as an effective supplement to traditional posterior open surgery. Ruetten et al. [9] reported the 2-year follow-up results of 87 patients with CRS treated by PPECD through a prospective study on the technical feasibility of PPECD. The results showed that 87.4% of the patients with upper arm pain disappeared, and only 9.2% of the patients had occasional pain, which not only achieved the decompression effect similar to open surgery, but also had small surgical trauma, fast recovery, and the recurrence rate was only 3.4%. As an alternative to conventional minimally invasive surgery, PPECD can be considered as an alternative. Based on prospective clinical observation, 88 patients with CRS treated by conventional microsurgical anterior decompression and fusion were reported in the second year. The two methods were randomly controlled. All patients were followed up for more than 2 years. There was no significant difference in the incidence of complications and postoperative revision between the two groups. However, PPECD has some clinical advantages, such as less trauma, less bleeding, shorter postoperative hospital stay and faster recovery.

In conclusion, compared with the traditional open surgery, PPECD has the following advantages: ① it can be carried out under local anesthesia, patients can keep awake during the operation, and can communicate with doctors in real time, which helps to avoid complications such as nerve root, spinal cord injury or spinal cord hypertension in time; ② The incidence of postoperative cervical segmental instability is greatly reduced with less damage to the posterior cervical muscles, no damage to the key structure of the articular process, but more grasp of the normal nucleus pulposus tissue in the intervertebral space; ③ there are no complications related to implants; ④ the whole spinal endoscope with water as the medium, clear vision, magnifying the tissue under the microscope, and can achieve the effect of complete decompression; ⑤ Postoperative hospital stay is short, recovery is fast and economic cost is low. However, compared with traditional open surgery, there are still risks of complications such as nerve root injury, dural sac tear, infection and bleeding; the indications are limited. For some cases, it is impossible to completely remove the protruding nucleus pulposus or calcified ligaments and other compressed tissues from the posterior approach. Instead, partial removal and indirect decompression with bone window may result in incomplete decompression. Researchers found that 90% of CSR patients with cervical spinal stenosis symptoms were relieved after posterior cervical incision, while maintaining the range of motion of the cervical spine, and minimizing the degeneration of adjacent segments, and the long-term effect was good. Therefore, posterior cervical

discectomy is an effective alternative surgery method [17].

In our study, the key to the treatment of CRS patients with PPECD is to achieve full decompression effect. The intervertebral foramen were dilated under endoscope to remove the nucleus pulposus. Therefore, the expansion of intervertebral foramen is a challenging problem for PPECD. Kim et al. [18] suggested that the "V" point at the junction of the upper and lower lamina adjacent to the articular process should be used as an anatomical mark. After removing the soft tissue around the V point, the working cannula should be expanded layer by layer under the guidance of endoscopy. In all patients in our study, drilling started at the median edge of the superior foramen with a radius of 3 to 4 mm. During the operation, the probe hook was used to examine the medial edge of the vertebral arch to prevent instability caused by excessive facetectomy. There are also studies that [19] at least 50% of the facet joints are reserved during the operation, which can effectively avoid the postoperative cervical segmental instability. Kim followed up 32 patients with PPECD for 25 months. The changes of cervical curvature, Cobb angle and intervertebral height were measured after operation. The results showed that more than 50% of facet joints were reserved in PPECD operation, which would not lead to excessive degeneration of cervical curvature after operation. The following points should be paid attention to in PPECD: (1) after entering the spinal canal, the fibrous tissue in the spinal canal should be cleaned to make the nerve root and dura clearly exposed; (2) the adhesion between ligamentum flavum and dural sac should be carefully separated to ensure that there is no dural sac tear; (3) the "V" point should be opened to ensure the placement of the channel, so as to avoid too small and excessive pushing of the spinal cord or nerve root; (4) Avoid excessive resection of the lateral intervertebral foramen, which may damage the venous plexus or vertebral artery around the vertebral artery, and avoid excessive resection leading to cervical instability. Research reports that PPECD often has postoperative complications such as nerve root injury, cerebrospinal fluid leakage, air embolism and so on, with an incidence rate of 2%-9% [20]. Our retrospective study has small sample size, short follow-up time and unclear long-term results.

35 patients with CSR were included in this study. No complications such as nerve root injury, dural sac injury and infection occurred during the operation. Postoperative pain and numbness of neck, shoulder and upper limbs were significantly relieved. During the follow-up period, no patients needed secondary minimally invasive or open surgery due to symptom recurrence. The "excellent and good rate" of the modified Macnab evaluation was 91.4%. Although the results of this study suggest that posterior cervical spine endoscopy is a safe and effective treatment for CSR, the following deficiencies exist in the design of this study: ① The patients were not included in the other treatment groups as the control group; ② the postoperative intervertebral disc height was not measured; ③ only NRS, NDI and JOA scores were counted in the follow-up indicators, and the pain related emotion scale indicators were not recorded, so as to further explore the pain related indicators. In view of the above shortcomings, it will be improved and perfected in the future research.

5. Conclusions

In conclusion, although it has been reported that both PPECD and ACDF are effective and safe surgical methods for the treatment of CSR, the former has less trauma and less intraoperative blood loss, which is a safe and effective surgical method and can effectively improve symptoms and patients' quality of life. Previous studies on posterior cervical spine endoscopy in the treatment of CSR were small sample studies or no long-term follow-up. Therefore, the long-term clinical efficacy of posterior cervical spine endoscopy in the treatment of CSR patients has not been clarified. In view of the limitations of this study, more samples and longer follow-up time will be needed in future studies.

Acknowledgments

Lanzhou Talent Innovation and Entrepreneurship Program, No.2020-RC-54. Study on residual symptoms after percutaneous spinal endoscopic treatment of lumbar intervertebral disc herniation treated by Guiqi Tongbi prescription.

Thanks for the support of the above funding.

Contributions

(I) Conception and design: W Zhang, X Wang; (II) Administrative support: X Wang; (III) Provision

of study materials or patients: X Wang; (IV) Collection and assembly of data: H Zhao, X You, G Zheng, T Sang, C Zhang; (V) Data analysis and interpretation: W Zhang, H Zheng, H Yang, W Chen; (VI) Manuscript writing: All authors; (VII) Final approval of manuscript: All authors.

These authors contributed equally to this work.

Correspondence

Xiangfu Wang, MD, Gansu Provincial Hospital of Traditional Chinese Medicine, 418 Guazhou Road, Qilihe District, Lanzhou, 730050, China.

Email: wangxf_1969@163.com.

References

- [1] Chen EL, Wang N, Quan RF. [Comparison of clinical effects of two anterior cervical decompression with fusion on treating two segment cervical spondylotic myelopathy]. *Zhongguo Gu Shang*. 2020 Sep 25;33(9):841-7.
- [2] Oliver JD, Goncalves S, Kerezoudis P, et al. Comparison of Outcomes for Anterior Cervical Discectomy and Fusion With and Without Anterior Plate Fixation: A Systematic Review and Meta-Analysis. *Spine (Phila Pa 1976)*. 2018 Apr 1;43(7):E413-E422.
- [3] Yang J, Liu P, Liu T, et al. [Effect of zero-profile and self-locking intervertebral cage and plate-cage construct on maintenance of cervical curvature after anterior cervical surgery]. *Zhongguo Xiu Fu Chong Jian Wai Ke Za Zhi*. 2020 Feb 15;34(2):151-156.
- [4] Yang X, Donk R, Arts MP, et al. Maintaining range of motion after cervical discectomy does not prevent adjacent segment degeneration. *Spine J*. 2019 Nov;19(11):1816-1823.
- [5] Ma X, Du Y, Wang S, et al. Adjacent segment degeneration after intervertebral fusion surgery by means of cervical block vertebrae. *Eur Spine J*. 2018 Jun;27(6):1401-1407.
- [6] Quillo-Olvera J, Lin GX, Kim JS. Percutaneous endoscopic cervical discectomy: a technical review. *Ann Transl Med*. 2018 Mar;6(6):100.
- [7] Quillo-Olvera J, Lin GX, Kim JS. Percutaneous endoscopic cervical discectomy: a technical review. *Ann Transl Med*. 2018 Mar;6(6):100.
- [8] Lin T, Wang Z, Chen G, et al. Predictive Effect of Cervical Sagittal Parameters on Conservative Treatment of Single-Segment Cervical Spondylotic Radiculopathy. *World Neurosurg*. 2020 Feb;134:e1028-e1036.
- [9] Oh JK, Hong JT, Kang DH, et al. Epidemiology of C5 Palsy after Cervical Spine Surgery: A 21-Center Study. *Neurospine*. 2019 Sep;16(3):558-562.
- [10] Chen YC, Wu JC, Chang HK, et al. Early Discharge for Anterior Cervical Fusion Surgery: Prediction of Readmission and Special Considerations for Older Adults. *Int J Environ Res Public Health*. 2019 Feb 21;16(4):641.
- [11] Hah RJ, Alluri R, Anderson PA. Biomechanical Analysis of an Anterior Cervical Discectomy and Fusion Pseudarthrosis Model Revised With Machined Interfacet Allograft Spacers. *Global Spine J*. 2020 Dec;10(8):973-981.
- [12] Zheng C, Huang X, Yu J, et al. Posterior Percutaneous Endoscopic Cervical Discectomy: A Single-Center Experience of 252 Cases. *World Neurosurg*. 2018 Dec;120:e63-e67.
- [13] Wen Z, Lu T, Wang Y, et al. Anterior Cervical Corpectomy and Fusion and Anterior Cervical Discectomy and Fusion Using Titanium Mesh Cages for Treatment of Degenerative Cervical Pathologies: A Literature Review. *Med Sci Monit*. 2018 Sep 12;24:6398-6404.
- [14] Lee JH, Lee SH. Clinical and radiographic changes after percutaneous endoscopic cervical discectomy: a long-term follow-up. *Photomed Laser Surg*. 2014 Dec;32(12):663-8.
- [15] Liu C, Liu K, Chu L, et al. Posterior percutaneous endoscopic cervical discectomy through lamina-hole approach for cervical intervertebral disc herniation. *Int J Neurosci*. 2019 Jul;129(7):627-634.
- [16] Yang JS, Chu L, Chen L, et al. Anterior or posterior approach of full-endoscopic cervical discectomy for cervical intervertebral disc herniation? A comparative cohort study. *Spine (Phila Pa 1976)*. 2014 Oct 1;39(21):1743-50.
- [17] Zheng C, Huang X, Yu J, et al. Posterior Percutaneous Endoscopic Cervical Discectomy: A Single-Center Experience of 252 Cases. *World Neurosurg*. 2018 Dec;120:e63-e67.
- [18] Kim CH, Shin KH, Chung CK, et al. Changes in cervical sagittal alignment after single-level posterior percutaneous endoscopic cervical discectomy. *Global Spine J*. 2015 Feb;5(1):31-8.

[19] Lee DH, Cho JH, Hwang CJ, et al. Multilevel posterior foraminotomy with laminoplasty versus laminoplasty alone for cervical spondylotic myelopathy with radiculopathy: a comparative study. *Spine J.* 2018 Mar; 18(3):414-421.

[20] Wu W, Yan Z. Intraoperative total spinal anesthesia as a complication of posterior percutaneous endoscopic cervical discectomy. *Eur Spine J.* 2018 Jul; 27(Suppl 3):431-435.